



International Journal of Surgery Science

E-ISSN: 2616-3470

P-ISSN: 2616-3462

© Surgery Science

www.surgeryscience.com

2018; 2(1): 37-39

Received: 13-11-2017

Accepted: 17-12-2017

Dr. SK Bhatia

Professor, Department of General Surgery, N.C. Medical College and Hospital, Israna, Panipat, Haryana, India
Email Id: skbhatia2606@gmail.com

Dr. Parmod Kumar

Assistant Professor, Department of General Surgery, Glocal Medical College And Super speciality Hospital and Research Center, Mirzapur Pole, Distt. - Saharanpur, Uttar Pradesh, India
Email Id: dr.parmodgarg@gmail.com

Assessment of biliary leakage after cholecystectomy

Dr. SK Bhatia and Dr. Parmod Kumar

DOI: <https://doi.org/10.33545/surgery.2018.v2.i1a.857>

Abstract

Background: Cholecystectomy is one of the most frequently performed procedures in gastrointestinal surgery, and the laparoscopic approach is now the gold standard for symptomatic cholelithiasis. The present study was conducted to assess biliary leakage after cholecystectomy.

Materials & Methods: 65 patients of biliary leakage after cholecystectomy of both genders were included. Parameters such as clinical presentations following biliary leak, timing of detection of bile leak post operatively, acute or chronic cholecystitis at the time of operation, amount of bile leak, duration of bile leak, postoperative investigation for bile leak, various modalities of management and its outcome, site of bile leak are recorded.

Results: Out of 65 patients, males were 38 and females were 27. Open cholecystectomy was performed in 32 and laparoscopic cholecystectomy in 33. Open method had 4 and laparoscopic cholecystectomy had 6 cases of major bile duct injury. The site of injury was GB Bed in 2, cystic duct in 4, CBD in 3 and CHD in 1 case. Management given was conservative with controlled external fistula in 35, suturing of cystic duct in 15, primary suturing in 10 and hepaticojejunostomy in 5 cases.

Conclusion: Bile leak from major bile duct injury should be managed promptly and requires skilled surgical intervention.

Keywords: Bile leak, bile duct injury, cholecystectomy

Introduction

Cholecystectomy is one of the most frequently performed procedures in gastrointestinal surgery, and the laparoscopic approach is now the gold standard for symptomatic cholelithiasis as well as for chronic and acute cholecystitis^[1]. Besides the advantages of a distinctly faster recovery and better cosmetic results, the laparoscopic approach bears a higher risk for iatrogenic bile duct injury (IBDI) and injury of the (right) hepatic artery^[2]. IBDI is a complication associated with significant perioperative morbidity and mortality, reduced long-term survival and quality of life, and high rates of subsequent litigation. Despite increasing experience and progress in laparoscopic skills of surgeons, the incidence of IBDI is still elevated compared to open cholecystectomy^[3]. The rate of clinically relevant bile leaks after conventional open cholecystectomy ranges between 0.1 and 0.5%. In contrast, biliary leakages have increased in the era of laparoscopic cholecystectomy (LC) by up to 3%^[4].

The first iatrogenic bile duct injury was described by Sprengel in 1891^[5]. Cholecystectomy whether laparoscopic or open is the most commonly performed hepatobiliary surgery. Therefore post operative biliary leakage is also more common following cholecystectomy. And also because of long learning curve of laparoscopic procedure, IBDI is on higher side in laparoscopic cholecystectomy than in open variety^[6]. Unrecognised or late diagnosis of bile duct injury can lead to serious consequences such as hepatic failure or death^[7]. The present study was conducted to assess biliary leakage after cholecystectomy.

Materials & Methods

The present study comprised of 65 patients of biliary leakage after cholecystectomy of both genders. The consent was obtained from all patients.

Data such as name, age, gender etc. was recorded. Operative and postoperative records were recorded. Parameters such as clinical presentations following biliary leak, timing of detection of bile leak post operatively, acute or chronic cholecystitis at the time of operation, amount of bile leak, duration of bile leak, postoperative investigation for bile leak, various modalities of management and its outcome, site of bile leak are recorded. Data thus obtained were subjected to statistical analysis. P value < 0.05 was considered significant.

Corresponding Author:

Dr. Parmod Kumar

Assistant Professor, Department of General Surgery, Glocal Medical College And Super speciality Hospital and Research Center, Mirzapur Pole, Distt. - Saharanpur, Uttar Pradesh, India
Email Id: dr.parmodgarg@gmail.com

Results

Table I: Distribution of patients

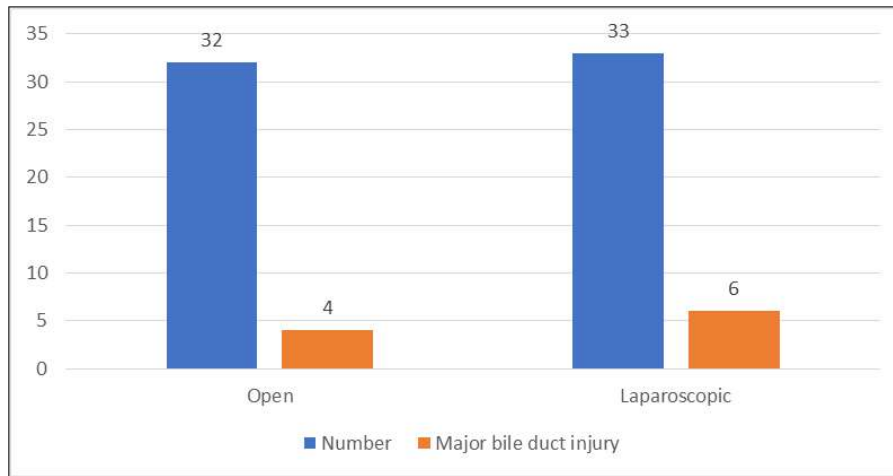
Total- 65		
Gender	Male	Female
M:F	38	27

Table I shows that out of 65 patients, males were 38 and females were 27.

Table II: Type of cholecystectomy and biliary leak

Method	Number	Major bile duct injury
Open	32	4
Laparoscopic	33	6

Table II shows that open cholecystectomy was performed in 32 and laparoscopic cholecystectomy in 33. Open method had 4 and laparoscopic cholecystectomy had 6 cases of major bile duct injury.



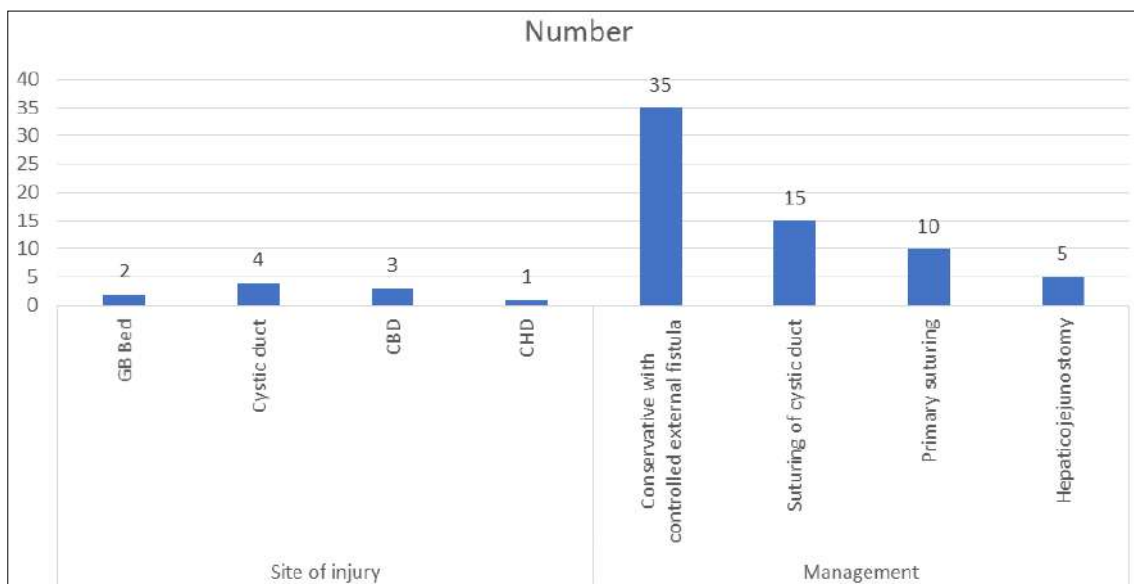
Graph I: Type of cholecystectomy and biliary leak

Table III: Assessment of parameters

Parameters	Variables	Number	P value
Site of injury	GB Bed	2	0.05
	Cystic duct	4	
	CBD	3	
	CHD	1	
Management	Conservative with controlled external fistula	35	0.02
	Suturing of cystic duct	15	
	Primary suturing	10	
	Hepaticojejunostomy	5	

Table III, graph II shows that site of injury was GB Bed in 2, cystic duct in 4, CBD in 3 and CHD in 1 case. Management given was conservative with controlled external fistula in 35,

suturing of cystic duct in 15, primary suturing in 10 and hepaticojejunostomy in 5 cases. The difference was significant ($P < 0.05$).



Graph II: Assessment of parameters

Discussion

Iatrogenic bile duct injuries (IBDI) after laparoscopic cholecystectomy (LC), being one of the most common performed surgical procedures, remain a substantial problem in gastrointestinal surgery^[8]. A variety of injuries can occur. Besides minor bile leakage of aberrant ducts, cystic stump or the main bile duct, complete occlusion of the main duct or a branch (often an aberrant right duct) can happen. In addition, bile duct strictures and biliary leakages are severe long-term complications after LC^[9]. These injuries are associated with high morbidity, mortality, and prolonged hospitalization. Currently, endoscopic procedures are most frequently used in the management of postoperative IBDI. There are several endoscopic techniques available, e.g. biliary stent placement, biliary sphincterotomy, and nasobiliary drainage^[10]. In this respect, endoscopic therapy can reduce the transpapillary pressure gradient and improve the transpapillary flow, which decreases the extravasation out of the biliary tract. This reduction of bile leakage allows healing of duct lesion injuries without direct surgical repair. The present study was conducted to assess biliary leakage after cholecystectomy.

In present study, out of 65 patients, males were 38 and females were 27. A large retrospective cohort analysis of nearly 1.6 million Medicare patients in the United States undergoing laparoscopic cholecystectomy from 1992-1999 confirmed the incidence rate of bile duct injury at 0.5%^[11]. Adamsen *et al.*^[12] found that bile duct injuries are more common following laparoscopic cholecystectomy, including fistulae, which are reported in 1.3% to 5.5% of cases.

We found that open cholecystectomy was performed in 32 and laparoscopic cholecystectomy in 33. Open method had 4 and laparoscopic cholecystectomy had 6 cases of major bile duct injury. We observed that site of injury was GB Bed in 2, cystic duct in 4, CBD in 3 and CHD in 1 case. Management given was conservative with controlled external fistula in 35, suturing of cystic duct in 15, primary suturing in 10 and hepaticojejunostomy in 5 cases. Efforts to improve safety in LC have greatly increased the body of knowledge regarding all factors relevant to cholecystectomy. These include timing of the procedure and patient selection as well as training and assessment of surgeons performing LC. Endeavors to increase safety of the procedure resulted in optimized intraoperative processes, such as photographic documentation of the 'critical view of safety' (CVS), first described by Strasberg and colleagues almost 20 years ago. Using the CVS technique, the Calot's triangle is completely unfolded by mobilizing the gallbladder neck from the gallbladder bed of the liver^[13]. When this view is achieved, the two structures entering the gallbladder (cystic duct and cystic artery) can be definitively detected. Importantly, it is not necessary to see the CBD since such a procedure may disturb bile duct perfusion^[14]. In addition to this standard procedure, the use of intraoperative cholangiography (IOC) has been propagated by some institutions. Several additional techniques are described to prevent IBDI during LC. Despite the plethora of publications and debates, there is still no consensus regarding the best setting and method, although most surgeons would agree that the CVS and IOC are among the most popular and effective. Both of these tools can be used via either laparotomy or laparoscopy^[15]. Other methods described include various dissection techniques (infundibular, antegrade, etc.), landmark techniques, Rouvière's sulcus, Calot's node, or use of ultrasound, just to name a few.

Conclusion

Authors found that bile leak from major bile duct injury should be managed promptly and requires skilled surgical intervention.

References

1. Branum G, Schmitt C, Baillie J, *et al.* Management of major biliary complications after laparoscopic cholecystectomy. *Ann Surg.* 1993;217:532-540.
2. Strasberg SM, Hertl M, Soper NJ. An analysis of the problem of biliary injury during laparoscopic cholecystectomy. *J Am Coll Surg.* 1995;180:101-125.
3. Karanikas M, Bozali F, Vamvakerou V, *et al.* Biliary tract injuries after lap cholecystectomy – types, surgical intervention and timing. *Ann Transl Med.* 2016;4:163.
4. Strasberg SM, Brunt LM. Rationale and use of the critical view of safety in laparoscopic cholecystectomy. *J Am Coll Surg.* 2010;211:132-138.
5. de Mestral C, Rotstein OD, Laupacis A, *et al.* Comparative operative outcomes of early and delayed cholecystectomy for acute cholecystitis: a population-based propensity score analysis. *Ann Surg.* 2014;259:10-15.
6. Barbier L, Souche R, Slim K, Ah-Soune P. Long-term consequences of bile duct injury after cholecystectomy. *J Visc Surg.* 2014;151:269-279.
7. da Costa DW, Dijkstra LM, Bouwense SA, *et al.* Cost effectiveness of same-admission versus interval cholecystectomy after mild gallstone pancreatitis in the PONCHO trial. *Brit J Surg.* 2016;103:1695-1703.
8. Mazer LM, Tapper EB, Sarmiento JM. Non-operative management of right posterior sectoral duct injury following laparoscopic cholecystectomy. *J Gastrointest Surg.* 2011;15:1237-1242.
9. Aggarwal R, Crochet P, Dias A, Misra A, Ziprin P, Darzi A. Development of a virtual reality training curriculum for laparoscopic cholecystectomy. *Brit J Surg.* 2009;96:1086-1093.
10. Woods MS, *et al.* Characteristics of biliary tract complications during laparoscopic cholecystectomy: a multi-institutional study. *Am J Surg.* 1994;167:27-34.
11. Flum DR, *et al.* Bile duct injury during cholecystectomy and survival in Medicare beneficiaries. *JAMA.* 2003;290:2168-2173.
12. Adamsen S, *et al.* Bile duct injury during laparoscopic cholecystectomy: a prospective nationwide series. *J Am Coll Surg.* 1997;184:571-578.
13. Fletcher DR, *et al.* Complications of cholecystectomy: risks of the laparoscopic approach and protective efforts of operative cholangiography. *Ann Surg.* 1999;229:449-457.
14. Walsh RM, *et al.* Trends in bile duct injuries from laparoscopic cholecystectomy. *J Gastrointest Surg.* 1998;2:458-462.
15. Carroll BJ, *et al.* Routine cholangiography reduces sequelae of common bile duct injuries. *Surg endoscopic.* 1996;10:1194-1197.